

**Hitachi Real-time Tissue
Elastography:
Publications & International
Communications
Clinical Abstracts**



HI-RTE

Hitachi Real-time Tissue Elastography

Hitachi Real-time Tissue Elastography for Liver Disease

NON-INVASIVE ASSESSMENT OF LIVER FIBROSIS IN A RAT MODEL: SHEAR WAVE ELASTICITY IMAGING VERSUS REAL-TIME ELASTOGRAPHY.

Lin SH, Ding H, Mao F, Xue LY, Lv WW, Zhu HG, Huang BJ, Wang WP.

Source

Department of Ultrasound, Zhongshan Hospital, Fudan University, Shanghai, China.

Abstract

The purpose of this study was to investigate the diagnostic value of shear wave elasticity imaging (SWEI) and real-time elastography (RTE) in liver fibrosis induced by dimethylnitrosamine (DMN) and to compare the accuracy of these methods. Seventy male Wistar rats given a single intra-peritoneal injection of DMN and 10 control rats given a saline injection underwent SWEI and RTE to determine their shear wave velocity (V_s) and liver fibrosis (LF) index, respectively. Correlations between V_s or the LF index and histologic stage of liver fibrosis (S0-S4) were analyzed, and the diagnostic values of the techniques were assessed using a receiver operating characteristic curve. A positive correlation was found between V_s and stage of liver fibrosis ($r = 0.947$, $p < 0.001$) and between LF index and stage (S) of liver fibrosis ($r = 0.662$, $p < 0.001$). For V_s , the areas under the receiver operating characteristic curve for the diagnosis of fibrosis, $S \geq S1$, $S \geq S2$, $S \geq S3$ and $S = S4$, were 0.983, 0.995, 0.999 and 0.964, respectively; for the LF index, the values were 0.871, 0.887, 0.761 and 0.839, respectively (all $p < 0.001$). V_s and the LF index values in rats with severe inflammatory activity were significantly higher than those in controls ($p < 0.001$). In conclusion, positive correlations exist between V_s or the LF index and the severity of liver fibrosis in rats. V_s is more accurate than the LF index in predicting liver fibrosis in rats. However, severe inflammatory activity may reduce the accuracy of both techniques.

Ultrasound Med Biol. 2013 Apr 18 [Epub ahead of print]

PERFORMANCE OF REAL-TIME STRAIN ELASTOGRAPHY, TRANSIENT ELASTOGRAPHY, AND ASPARTATE-TO-PLATELET RATIO INDEX IN THE ASSESSMENT OF FIBROSIS IN CHRONIC HEPATITIS C.

Ferraioli G, Tinelli C, Malfitano A, Dal Bello B, Filice G, Filice C; Liver Fibrosis Study Group, Above E, Barbarini G, Brunetti E, Calderon W, Di Gregorio M, Lissandrin R, Ludovisi S, Maiocchi L, Michelone G, Mondelli M, Patruno SF, Perretti A, Poma G, Sacchi P, Zaramella M, Zicchetti M.

Source

Ultrasound Unit, Infectious Diseases Department, Fondazione IRCCS Policlinico San Matteo, University of Pavia, Via Taramelli 5, Pavia 27100, Italy. giovanna.ferraioli@unipv.it

Abstract

OBJECTIVE:

The purpose of this article is to evaluate the diagnostic performance of transient elastography, real-time strain elastography, and aspartate-to-platelet ratio index in assessing fibrosis in patients with chronic hepatitis C by using histologic Metavir scores as reference standard.

SUBJECTS AND METHODS:

Consecutive patients with chronic hepatitis C scheduled for liver biopsy were enrolled. Liver biopsy was performed on the same day as transient elastography and real-time strain elastography. Transient elastography and real-time strain elastography were performed in the same patient encounter by a single investigator using a medical device based on elastometry and an ultrasound machine, respectively. Diagnostic performance was assessed by using receiver operating characteristic curves and area under the receiver operating characteristic curve (AUC) analysis.

RESULTS:

One hundred thirty patients (91 men and 39 women) were analyzed. The cutoff values for transient elastography, real-time strain elastography, and aspartate-to-platelet ratio index were 6.9 kPa, 1.82, and 0.37, respectively, for fibrosis score of 2 or higher; 7.3 kPa, 1.86, and 0.70, respectively, for fibrosis score of 3 or higher; and 9.3 kPa, 2.33, and 0.70, respectively, for fibrosis score of 4. AUC values of transient elastography, real-time strain elastography, aspartate-to-platelet ratio index were 0.88, 0.74, and 0.86, respectively, for fibrosis score of 2 or higher; 0.95, 0.80, and 0.89, respectively, for fibrosis score of 3 or higher; and 0.97, 0.80, and 0.84, respectively, for fibrosis score of 4. A combination of the three methods, when two of three were in agreement, showed AUC curves of 0.93, 0.95, and 0.95 for fibrosis scores of 2 or higher, 3 or higher, and 4, respectively.

CONCLUSION:

Transient elastography, real-time strain elastography, and aspartate-to-platelet ratio index values were correlated with histologic stages of fibrosis. Transient elastography offered excellent diagnostic performance in assessing severe fibrosis and cirrhosis. Real-time elastography does not yet have the potential to substitute for transient elastography in the assessment of liver fibrosis

AJR Am J Roentgenol. 2012 Jul;199(1):19-25.

LIVER ELASTICITY IN NASH PATIENTS EVALUATED WITH REAL-TIME ELASTOGRAPHY (RTE).

Orlacchio A, Bolacchi F, Antonicoli M, Coco I, Costanzo E, Tosti D, Francioso S, Angelico M, Simonetti G.

Department of Diagnostic Imaging, Molecular Imaging, Interventional Radiology, and Radiation Therapy, University Hospital Tor Vergata, Rome, Italy. aorlacchio@uniroma2.it

Abstract

Liver elasticity as assessed by real-time elastography (RTE) has been shown to be correlated to liver fibrosis in various chronic liver diseases. The aim of our study was to assess the RTE performance in the evaluation of liver fibrosis in nonalcoholic steatohepatitis (NASH), as well as the histopathologic variables determining the eventual discordance between the RTE-predicted and the biopsy-proven fibrosis. Fifty-two consecutive biopsy proven NASH patients and 20 controls were studied. Liver tissue elasticity measurements were performed using the Hitachi EUB-8500 sonographer and the EUP-L52 Linear (3-7 MHz) probe. RTE liver tissue mean elasticity (TME) values were calculated and correlated to the histologic fibrosis, activity and steatosis scores. A decrease in TME was observed with increasing fibrosis ($r = -0.75$). Similarly, TME varied together consistently with steatosis ($r = -0.3$). In contrast, TME did not show any correlation with the severity of inflammation. Multiple regression analysis showed that fibrosis was the only variable able to significantly ($p < 0.0001$) modify TME values. The diagnostic accuracy of TME measurement for $F > 0$ evaluated by AUC-ROC analysis was 0.86. The diagnostic accuracy of TME measurement for $F \geq 2$ was 0.92. We suggest that RTE could be used as a complementary imaging method to evaluate liver fibrosis in NASH patients. Future studies of larger patient cohorts are necessary for the validation of the technique.

REAL-TIME TISSUE ELASTOGRAPHY FOR EVALUATION OF HEPATIC FIBROSIS AND PORTAL HYPERTENSION IN NON-ALCOHOLIC FATTY LIVER DISEASES.

Ochi H, Hirooka M, Koizumi Y, Miyake E, Tokumoto Y, Soga Y, Tada F, Abe M, Hiasa Y, Onji M.

Department of Gastroenterology and Metabology, Ehime University Graduate School of Medicine.

Abstract

The purpose of this study was to prospectively measure liver stiffness with real-time tissue elastography in patients with non-alcoholic fatty liver diseases (NAFLD), and to compare the result with clinical assessment of fibrosis using histological stage. One hundred and eighty-one prospectively enrolled patients underwent real-time tissue elastography, with the first 106 patients being analyzed as the training set and the remaining 75 being evaluated as the validation set. Hepatic and splenic elastic ratios were calculated and compared with stage of histological fibrosis. Portal hypertension was assessed. Real-time tissue elastography cutoff values by stage in the training set were 2.47 for F1, 2.67 for F2, 3.02 for F3 and 3.36 for F4. Using these cutoff values, the diagnostic accuracy of hepatic fibrosis in the validation set was 82.6% - 96.0% in all stages. Only portal fibrosis correlated with the hepatic elastic ratio by multivariate analysis. The area under the curve (AUC) of the receiver operating characteristic (ROC) curve of elastic ratio better correlated than serum fibrosis markers in both early and advanced fibrosis stages. Patients with portal hypertension, defined by splenic elasticity, had early fibrosis. Patients with severe portal hypertension were found only in the cirrhotic group. Conclusion: Real-time tissue elastography is useful in evaluating hepatic fibrosis and portal hypertension in patients with NAFLD.

Hepatology. 2012 Apr 5. doi: 10.1002/hep.25756. [Epub ahead of print]

REAL-TIME ELASTOGRAPHY WITH A NOVEL QUANTITATIVE TECHNOLOGY FOR ASSESSMENT OF LIVER FIBROSIS IN CHRONIC HEPATITIS B.

Wang J, Guo L, Shi X, Pan W, Bai Y, Ai H.

Department of Ultrasonography, The First Affiliated Hospital of Medical College, Xi'an Jiaotong University, Shaanxi 710061, China.

Abstract

BACKGROUND:

The accurate evaluation of liver fibrosis stage is important in determining the treatment strategy. The limitations of percutaneous liver biopsy as the gold standard are obvious for invasion. Real-time elastography with conventional ultrasound probes and a new quantitative technology for diffuse histological lesion is a novel approach for staging of liver fibrosis.

PURPOSE:

This study aimed to evaluate the value of real-time tissue elastography with a new quantitative technology for the assessment of liver fibrosis stage.

MATERIALS AND METHODS:

Real-time elastography was performed in 55 patients with liver fibrosis and chronic hepatitis B and in 20 healthy volunteers. Eleven parameters for every patient in colorcode image obtained from the real-time elastography were analyzed with principal components analysis. We analyzed the correlation between elasticity index and liver fibrosis stage and the accuracy of real-time elastography for liver fibrosis staging. Additionally, aspartate transaminase-to-platelet ratio index was also included in the analysis.

RESULTS:

The Spearman's correlation coefficient between the elasticity index and the histologic fibrosis stage was 0.81, which is highly significant ($p < 0.001$). The areas under receiver operating characteristic curves indicating diagnostic accuracy were 0.93 ($F \geq F1$, $p < 0.001$) for the diagnosis of liver fibrosis, 0.92 ($F \geq F2$, $p < 0.001$), 0.84 ($F \geq F3$, $p < 0.05$) and 0.66 ($F = F4$, $p > 0.05$), respectively.

CONCLUSIONS:

Real-time elastography with a new quantitative technology for diffuse histological lesion is a new and promising sonography-based noninvasive method for the assessment of liver fibrosis in patients with chronic hepatitis B

Eur J Radiol. 2012 Jan;81(1):e31-6. Epub 2011 Jan 7.

REAL-TIME ELASTOGRAPHY FOR DIAGNOSIS OF LIVER FIBROSIS IN CHRONIC HEPATITIS B.

Xie L, Chen X, Guo Q, Dong Y, Guang Y, Zhang X.

Department of Ultrasound, Shengjing Hospital of China Medical University, 36 Sanhao St 110004, Shenyang, Liaoning, China.

OBJECTIVES:

The purpose of this study was to prospectively investigate the value of real-time ultrasound elastography for diagnosis of liver fibrosis in patients with chronic hepatitis B and to correlate the elastographic findings with histologic stages of liver fibrosis and blood parameters.

METHODS:

Liver biopsies, blood testing, and real-time elastography were performed in 71 patients with chronic viral hepatitis B and liver cirrhosis. The ratio of the elastic strain of liver tissue to that of muscle tissue was determined and correlated with the histologic fibrosis stages and laboratory examination results.

RESULTS:

There was a highly negative correlation between the elastic strain ratio and the histologic fibrosis stage (Spearman $r = -0.702$; $P < .001$). There was a high correlation observed between a decreasing elastic strain ratio and an increasing fibrosis stage. With substantial liver fibrosis (Scheuer score $\geq S2$) and cirrhosis (S4) as diagnostic criteria, the areas under the receiver operating characteristic curves (AUCs) of the elastic strain ratios were 0.863 and 0.797, respectively. The AUC for substantial fibrosis

was higher than the AUC for the blood parameters used to diagnose substantial liver fibrosis. Elastic strain ratio cutoff values of 1.10 and 0.60 were identified as diagnostic of substantial fibrosis and cirrhosis, respectively, with sensitivities of 77.8% and 50.0%, respectively, and specificities of 80.0% and 96.7%.

CONCLUSIONS:

Real-time elastography is a new clinically promising and noninvasive method for quantitative assessment of liver fibrosis.

J Ultrasound Med. 2012 Jul;31(7):1053-60.

NONINVASIVE EVALUATION OF HEPATIC FIBROSIS IN PATIENTS WITH HEPATITIS C USING ELASTOGRAPHY

Hussein Okasha, Mohamed Naguib Abdalla, Nagwa Ramadan and Waleed El-Nabwey

Department of Internal Medicine, Faculty of Medicine, Cairo University, Cairo and
Department of Internal Medicine, Faculty of Medicine, Beni Suef University, Beni Suef, Egypt

Background

Evaluation of the static elastography as a noninvasive method for predicting liverfibrosis in patients with hepatitis C virus as an alternative modality for liver biopsy.

Materials and methods

A group of 35 patients with chronic hepatitis C virus were subjected to biological tests, abdominal ultrasonographic examination, liver biopsy with a histopathological estimation of score of activity and fibrosis, and liver stiffness measurement by means of elastography of the left lobe of the liver.

Results

Our study showed that there is a significant association between the elastography score and the grade of fibrosis ($P= 0.001$). A significant positive relationship was found between the activity stage and the elastography score ($r = 0.625$ and $P = 0.01$). Elastography has been shown to have a reasonably high sensitivity, specificity, and diagnostic accuracy 100, 48.27, and 57.14% and 87.5, 96.3, and 94.29% for fibrosis grades 0, 1, 2 and 5, 6, respectively. No statistically significant relationship was found between the diameter of the anterior abdominal wall and the accuracy of elastography. However, 63.6% of those with bright liver texture had an incorrect elastography score, whereas 42.9% of those with a normal liver texture had the correct elastography score, and this association was statistically significant ($P = 0.039$).

Conclusion

Transient elastography indicates whether the liver is normal or cirrhotic; however, it has a low accuracy in the assessment of moderate stages of fibrosis (stages II, III, and IV). Bright liver affects the accuracy of elastography in assessing the degree of fibrosis, whereas anterior abdominal wall diameter does not.

Egypt J Intern Med 2012;24:79–82

HEAD-TO-HEAD COMPARISON OF TRANSIENT ELASTOGRAPHY (TE), REAL-TIME TISSUE ELASTOGRAPHY (RTE), AND ACOUSTIC RADIATION FORCE IMPULSE (ARFI) IMAGING IN THE DIAGNOSIS OF LIVER FIBROSIS.

Colombo S, Buonocore M, Del Poggio A, Jamoletti C, Elia S, Mattiello M, Zabbialini D, Del Poggio P.

BACKGROUND:

Real-time tissue elastography (RTE), acoustic radiation force impulse (ARFI) imaging, and transient elastography (TE) are new technologies that are used for liver stiffness evaluation. The aim of this study was to compare these methods in the same population and to determine their diagnostic accuracy in the prediction of liver fibrosis.

METHODS:

Forty-five consecutive, previously biopsied, patients with chronic liver disease and 27 normal subjects underwent TE, RTE, and ARFI on the right liver lobe. Correlation coefficients between measurements, Metavir fibrosis stage, and histological necro-inflammatory activity (adjusted for fibrosis stage) were evaluated via Spearman's rank order correlation coefficients. Areas under the receiver operating characteristic curve (AUROCs) were calculated to predict each fibrosis stage.

RESULTS:

Failure or inconsistent results occurred in 12.5% of the attempts at TE, but in none of the attempts at RTE and ARFI. The three methods showed high correlation with fibrosis and poor correlation with necro-inflammatory activity. TE and ARFI exhibited high diagnostic accuracy (AUROCs ≥ 0.9) in diagnosing cirrhosis (F4 Metavir). All three methods presented fair (AUROCs > 0.7) to good (AUROCs > 0.8) diagnostic accuracy in diagnosing fibrosis (F1-4 Metavir) and significant fibrosis (F2-4 Metavir), with TE showing the best performance (AUROCs were 0.878 for fibrosis and 0.897 for significant fibrosis).

CONCLUSIONS:

TE and ARFI provide high diagnostic accuracy in the diagnosis of cirrhosis. When feasible, TE may perform better than RTE and ARFI in predicting fibrosis and significant fibrosis, but larger studies are needed

J Gastroenterol. 2012 Jan 6. [Epub ahead of print]

SPLENIC ELASTICITY MEASURED WITH REAL-TIME TISSUE ELASTOGRAPHY IS A MARKER OF PORTAL HYPERTENSION

Masashi Hirooka, MD, PhD, Hironori Ochi, MD, Yohei Koizumi, MD, PhD, Yoshiyasu Kisaka, MD, PhD, Masanori Abe, MD, PhD, Yoshio Ikeda, MD, PhD, Bunzo Matsuura, MD, PhD, Yoichi Hiasa, MD, PhD and Morikazu Onji, MD, PhD

Abstract

Purpose: To prospectively correlate spleen elasticity and degree of portal hypertension estimated with the hepatic venous pressure gradient (HVPG) and to evaluate spleen elasticity as a predictor of gastroesophageal varices.

Materials and Methods: The institutional review board approved this study, and patients provided written informed consent. In a pilot study of 60 patients with chronic liver damage, the authors measured liver and spleen elasticity with real-time tissue elastography (RTE), obtained serum markers related to fibrosis, examined hepatic and splenic blood flow with duplex Doppler ultrasonography, estimated HVPG, and performed upper gastrointestinal endoscopy. Then, with use

of thresholds determined in the pilot study, the authors conducted a validation trial with another 210 patients, performing all studies except the measurement of HPVG. The relationship between HPVG and the other parameters was analyzed. Sensitivity, specificity, positive predictive value (PPV), and negative predictive value (NPV) in the diagnosis of gastroesophageal varices were calculated by using cutoff values obtained from receiver operating characteristic curves.

Results: Among the parameters associated with HPVG, correlation was closest with splenic elasticity ($R = 0.854$, $P < .0001$). When 8.24 was selected as the cutoff of splenic elasticity for predicting HPVG of more than 10 mm Hg, the accuracy of diagnosing gastroesophageal varix was 90% (sensitivity, 96%; specificity, 85%; PPV, 83%; NPV, 97%). The results of the validation trial showed that the 8.24 cutoff for splenic elasticity was associated with a diagnostic accuracy of 94.8% (sensitivity, 98%; specificity, 93.8%; PPV, 82.1%; NPV, 99.4%) for gastroesophageal varices.

Conclusion: Splenic elasticity determined with RTE is the most closely associated parameter for evaluating HPVG and is useful as a clinical marker of portal hypertension and a predictive marker of gastroesophageal varices.

Radiology 2011;261 960-968

REAL-TIME TISSUE ELASTOGRAPHY AS A TOOL FOR THE NONINVASIVE ASSESSMENT OF LIVER STIFFNESS IN PATIENTS WITH CHRONIC HEPATITIS C.

Morikawa H, Fukuda K, Kobayashi S, Fujii H, Iwai S, Enomoto M, Tamori A, Sakaguchi H, Kawada N.

Source

Department of Hepatology, Graduate School of Medicine, Osaka City University, 1-4-3 Asahimachi, Abeno, Osaka 545-8585, Japan.

Abstract

BACKGROUND:

Although histopathological examination by "invasive" liver biopsy remains the gold standard for evaluating disease progression in chronic liver disease, noninvasive tools have appeared and have led to great progress in diagnosing the stage of hepatic fibrosis. The aim of this study was to assess the value of real-time tissue elastography, using an instrument made in Japan, for the visible measurement of liver elasticity; in particular, comparing the results with those of transient elastography (Fibroscan).

METHODS:

Real-time tissue elastography (RTE), transient elastography (Fibroscan), liver biopsy, and routine laboratory analyses were performed in 101 patients with chronic hepatitis C. The values for tissue elasticity obtained using novel software (Elasto_ver 1.5.1) connected to RTE were transferred to four image features, Mean, Standard Deviation (SD), Area, and Complexity. Their association with the stage of fibrosis at biopsy and with liver stiffness (kPa) obtained by Fibroscan was analyzed.

RESULTS:

Colored images obtained by RTE were classified into diffuse soft, intermediate, and patchy hard patterns and the calculated elasticity differed significantly between patients according to and

correlated with the stages of fibrosis ($p < 0.0001$). Mean, SD, Area, and Complexity showed significant differences between the stages of fibrosis (Tukey-Kramer test, $p < 0.05$). In discriminating patients with cirrhosis, the areas under the receiver operating characteristic curves (AUC) were 0.91 for Mean, 0.84 for SD, 0.91 for Area, 0.93 for Complexity, and 0.95 for Fibroscan.

CONCLUSIONS:

RTE is a noninvasive instrument for the colored visualization of liver elasticity in patients with chronic liver disease.

J Gastroenterol. 2011 Mar;46(3):350-8. Epub 2010 Aug 10.

LIVER FIBROSIS ASSESSMENT WITH REAL-TIME TISSUE ELASTOGRAPHY AND IMAGE ANALYSIS QUANTIFICATION IN CHRONIC HEPATITIS C

M. Mori K. Fukuda S. Hashimoto A. Tonomura T. Mitake

Purpose

Liver biopsy is a gold standard for evaluating the degree of fibrosis in chronic hepatitis C (CH-C). Recent reports have revealed that Real-time Tissue Elastography (RTE: Hitachi Medical Co., Japan) is a powerful tool for quantitative evaluation of tissue elasticity. In this study, we quantitatively assessed liver fibrosis of CH-C with RTE, compared with the percentage of liver fibrosis calculated by a digital image analysis system (Image J: NIH).

Material & Methods

Subjects were 26 CH-C patients (21 CH and 5LC) who had undergone liver biopsy with informed consent. We performed RTE using Hitachi EUB-8500 and EUP-L52 linear probe, scanned liver in the right intercostal region with a slight compression, obtained color strain images and analyzed them quantitatively by an image analysis software. The percentage of liver fibrosis was calculated by Image J on Azan-stained specimens and compared with the obtained various strain parameters (mean and standard deviation of relative strain, area of hard region, and mean of complexity).

Results

Mean of relative strain was closely correlated with the percentage of liver fibrosis ($r = -0.56$, $P < 0.01$). Other strain parameters were also well correlated with the degree of liver fibrosis ($P < 0.01$).

Conclusion

RTE is a promising non-invasive tool which makes it possible to assess liver fibrosis quantitatively.

Ultrasound in Medicine and Biology August 2011, Volume 37, Issue 8, Supplement, Page S79

HEPATIC ELASTICITY IN PATIENTS WITH ASCITES: EVALUATION WITH REAL-TIME TISSUE ELASTOGRAPHY.

Hirooka M, Koizumi Y, Hiasa Y, Abe M, Ikeda Y, Matsuura B, Onji M.

Department of Gastroenterology and Metabology, Ehime University Graduate School of Medicine, Shitsukawa, Toon, Ehime 791-0295, Japan.

OBJECTIVE:

Transient elastography is a rapid, noninvasive, and reproducible approach to assessment of liver fibrosis by measurement of liver elasticity. However, transient elastographic measurements are of limited utility in patients with ascites or severe obesity. The aim of this study was to determine whether measurements of liver stiffness with real-time tissue elastography can be altered for patients with ascites.

SUBJECTS AND METHODS:

The subjects were 54 patients being treated at a university hospital between January and December 2009. In 42 patients, real-time tissue elastography to evaluate liver stiffness was performed before and after injection to produce artificial ascites for radiofrequency ablation. The other 12 patients had ascites due to cirrhosis, and liver stiffness was measured with real-time tissue elastography before and after control of ascites.

RESULTS:

Elastic ratios evaluated with real-time tissue elastography did not differ significantly before and after injection for artificial ascites or before and after control of ascites. This ratio was the same for patients with and those without cirrhosis and was unaffected by distance between the body surface and the targeted liver area. Stable values thus were measured with real-time tissue elastography.

CONCLUSION:

Liver stiffness can be measured reproducibly with real-time tissue elastography even in patients with ascites. This method has the potential of being superior to transient elastography for assessment of liver stiffness, particularly in patients with decompensated cirrhosis.

AJR Am J Roentgenol. 2011 Jun;196(6):W766-71.

REAL-TIME ELASTOGRAPHY CAN CLEAR HEPATIC ASCITES HURDLE

By Erik L. Ridley, AuntMinnie staff writer

May 25, 2011 -- In contrast to transient elastography methods, real-time elastography can reliably measure liver stiffness in patients with ascites, according to research published in the June edition of the *American Journal of Roentgenology*.

A group from Ehime University Graduate School of Medicine in Japan found that real-time elastography produced similar elasticity ratios before and after artificial ascites were implanted for radiofrequency ablation. Similar results were also found in patients with ascites from cirrhosis.

"This method has the potential of being superior to transient elastography for assessment of liver stiffness, particularly in patients with decompensated cirrhosis," wrote the research team led by Dr. Masashi Hirooka (*AJR*, June 2011, Vol. 196:6, pp. W766-W771).

While transient elastography can effectively assess liver fibrosis by measuring liver elasticity, the technique is limited in severely obese patients or those with ascites (an excessive accumulation of fluid); elastic waves do not propagate through liquids. Real-time elastography, however, has more potential for precisely evaluating liver stiffness because it transmits numerous pulses and utilizes mean values of the frames, according to the authors.

In addition, elasticity can be measured with slight compression or relaxation of the body. Echo signals are captured in real-time, and the technique facilitates anatomic correlations by simultaneously displaying tissue elasticity images and conventional B-mode images, according to the group.

To test if real-time tissue elastography could sufficiently evaluate liver stiffness in patients with ascites, the researchers evaluated 54 patients who were being treated at their university hospital from January to December 2009.

Of these 54 patients, 42 received real-time elastography to assess liver stiffness before and after injection to produce artificial ascites for radiofrequency ablation. The remainder had ascites due to cirrhosis and underwent real-time elastography before and after control of ascites, according to the authors.

Hepatic elasticity was measured with an EUB-7500 ultrasound scanner (Hitachi Medical Systems), using an EUP-L52 linear probe (Hitachi) with a central frequency of 5.5 MHz. B-mode was utilized first to visualize the liver, followed by the elastographic mode.

The researchers determined that the mean elastic ratio was 3.78 ± 0.87 before artificial ascites injection and 3.75 ± 0.76 afterward. The difference was not statistically significant ($p = 0.973$).

In the 12 patients who had ascites due to cirrhosis, the mean elastic ratio was 5.46 ± 0.52 before ascites was controlled and 5.51 ± 0.45 afterward. The difference also was not statistically significant ($p = 0.766$).

In both patient groups, neither the amount of ascites nor the distance between the abdominal skin and liver surface appeared to influence the elastic ratio.

"Stable values thus were measured with real-time tissue elastography," the authors wrote.

The researchers concluded that real-time elastography can reproducibly measure liver stiffness, even in patients with ascites.

"Because transient elastography cannot be used to evaluate liver stiffness in patients with cirrhosis and ascites, the real-time tissue elastographic method may have better potential than transient elastography for identification of liver stiffness," the authors wrote.

"Moreover, real-time tissue elastography is noninvasive and is associated with less sampling error than liver biopsy and thus has advantages for both clinicians and patients when data on liver stiffness are needed to determine suitable treatment and evaluate prognosis," they concluded.

INTRAOPERATIVE APPLICATIONS OF FREEHAND REAL-TIME ELASTOGRAPHY FOR SMALL FOCAL LIVER LESIONS: AN INITIAL REPORT OF MINI-LINEAR PROBE FOR INTRAOPERATIVE USE

Y. Inoue, J. Arita, J. Kaneko, S. Tamura, T. Aoki, Y. Beck, K. Hasegawa, Y. Sugawara, N. Kokudo; Tokyo/JP

Purpose: Freehand real-time elastography (RTE) has seldom been used in intraoperative setting due to absence of small-sized probe for intraoperative use. We describe intraoperative RTE applied to small focal lesions.

Methods and Materials: We applied two distinct methods of RTE systems intraoperatively. One was a spatial cross-correlation method (SCM) equipped with a compression quality feedback function that checks the quality and quantity of the external compression. The other was combined auto-correlation method (CAM), which is globally accepted as the promising diagnostic method for breast lesions. The mini-linear 7.5-MHz probes were newly developed for both imaging methods, and these two methods were applied intraoperatively. From November 2006 to March 2008, SCM-RTE was performed for 27 adenocarcinomas, 18 hepatocellular carcinomas (HCCs), and 11 benign lesions after routine B-mode intraoperative ultrasonography (IOUS). We then evaluated the compliance of the RTE findings with the pathological diagnosis. CAM-RTE was introduced to our department from September, 2010.

Results: SCM-RTE images were obtained for all the lesions except for one metastatic adenocarcinoma. For 15 lesions, clear images were difficult to obtain using B-mode IOUS, whereas SCM-RTE clearly visualized the differences in elasticity.

Conclusion: SCM-RTE system facilitated the successful freehand RTE of liver lesions in an intraoperative setting, enabling “visual palpation” during liver surgery and serving as a supportive modality for B mode IOUS. We will present the results of CAM-RTE additionally.

ECR 2011, March 4th – 7th, Vienna

LIVER FIBROSIS IN PATIENTS WITH CHRONIC HEPATITIS C: NONINVASIVE DIAGNOSIS BY MEANS OF REAL-TIME TISSUE ELASTOGRAPHY—ESTABLISHMENT OF THE METHOD FOR MEASUREMENT

Yohei Koizumi , MD, Masashi Hirooka , MD, PhD, Yoshiyasu Kisaka , MD, PhD, et al

Purpose: To prospectively measure liver stiffness with real-time tissue elastography in patients with chronic hepatitis C and to compare the results with those of clinical assessment of fibrosis by using histologic stage as the reference standard.

Materials and Methods: All subjects gave informed consent, and the study was approved by the institutional ethics committee. Seventy hospitalized patients (46 men, 24 women; mean age, 65.5 years \pm 11.7 [standard deviation]; age range, 33–87 years) with chronic hepatitis C underwent real-time elastography between January 2009 and September 2009. Elastography was performed at four liver locations by two independent observers. The elastic ratio (ratio of the value in the intrahepatic venous small vessels divided by the value in the hepatic parenchyma) was calculated and was compared with histologic fibrosis stage at liver biopsy. The elastic ratio and clinical fibrosis markers were assessed by using receiver operating characteristic (ROC) analysis. The differences between body site and observers were assessed with κ statistics and intraclass correlation coefficients (ICCs). Results: Real-time tissue elastography cutoff values were 2.73 for F of 2 or greater, 3.25 for F of 3 or greater, and 3.93 for F of 4. No site differences were observed ($\kappa = 0.835$, ICC = 0.966), and the elastic ratio measurement was correlated between the two examiners ($r^2 = 0.869$, $P = .0001$). The areas under the ROC curves for elastic ratio, hyaluronic acid, type IV collagen, aspartate aminotransferase-to-platelet ratio index, FibroIndex, Forns score, and Hepascore were 0.95, 0.32, 0.73, 0.76, 0.76, 0.87, and 0.70, respectively; the elastic ratio performed better than the serum fibrosis markers and other scores.

Conclusion: Real-time tissue elastography is not invasive and could be used to evaluate liver fibrosis in patients with chronic hepatitis C.

Radiology: Volume 258: Number 2, 610 - 617—February 2011

REAL TIME SONOELASTOGRAPHY IN THE DIFFERENTIATION OF FOCAL LIVER LESIONS

Larisa Sandulescu(1), A Saftoiu (1), I Rogoveanu (7), O1 Gheonea (I), fv1 Filip (I), Slordache (1), C Oumitrescu (1), T Ciurea (1)

(1) Research Center in Gastroenterology and Hepatology, Romania

Introduction: Elasticity measurements have been already reported to be useful for the diagnosis and differentiation of many tumors but there are only few studies for the focal liver lesions. The aim of the study was to analyze whether computer enhanced dynamic analysis of elastography images is able to better characterize and differentiate benign and malignant liver lesions.

Material and methods: The study group included, in total forty two liver tumors : 8 hepatocellular carcinoma, 2 cholangiocarcinoma, 22 liver metastases and 10 haemangiomas. RTE was performed by EUS (2 cholangiocarcinoma, 8 liver metastases and 2 haemangiomas) or transabdominal ultrasound (8 hepatocellular carcinoma, 8 haemangiomas 14 liver metastases). ROC analysis for the mean hue obtained through histogram analysis of the region of interest (liver lesion) after averaging individual pixels over a 10-second elastography movies was used to assess the color information inside the region of interest and to consequently differentiate benign and malignant liver lesions.

Results: The mean values of the histogram analysis for hepatocellular carcinoma, cholangiocarcinoma,

metastases and haemangioma was: $187,71 \pm 24,72$; $208,93 \pm 18,22$; $204,29 \pm 16,99$ and $161,42 \pm 26,72$ respectively. The accuracy of real time elastography in the differentiation of benign and malignant masses was good, with areas under the receiver operating curve of 0,859.

In conclusion, real time sonoelastography is a promising technique that might improve the characterization and

differentiation between benign and malignant focal liver lesions visualized during transabdominal or endoscopic ultrasound.

Euroson 2010, August 22 – 25, Copenhagen

REAL-TIME SONO-ELASTOGRAPHY FOR NON INVASIVE ASSESSMENT OF DIFFUSE LIVER DISEASE

Larisa Sandulescu(1), A Saftoiu (1), I Rogoveanu (1), A Amzoloni (1), O-1 Gheonea (1), A Oproaica (1), M Ene (1), M tonescu (1), T Ciurea (1)

(1) Research Center in Gastroenterology and Hepatology, Romania

The aim of this study was to analyze whether the new real time ultrasound system - Hitachi HI VISION Preirus- is able to differentiate between different degrees of liver fibrosis.

Material and methods: A total of 67 patients were enrolled in this study. Histological assessment of liver fibrosis was performed by liver biopsy in all patients, except those with nonalcoholic steatohepatitis and healthy voluntaries. Liver fibrosis was staged on Metavir score: F1 - 5 patients, F1 - 12 patients, F3- 12 patients, F4- 14 patients. Thirteen healthy voluntaries and 13 patients with steatohepatitis being added to this group. EUS elastography equipment includes a Hitachi HI VISION Preirus ultrasound system. Two movies were recorded for every patient, one movie by intercostal approach and the other by epigastric approach.

Results: Due to the limitations of the method we not obtained elastography information in 6 patients (8.96%). The mean values of the histogram analysis for healthy voluntaries, steatohepatitis, FO, F1, F2, F3 and F4 was: $133,74 \pm 13,62$; $141,09 \pm 21,50$; $137,69 \pm 8,67$; $138,13 \pm 11,44$; $134,47 \pm 18,84$; $179,31 \pm 19,93$ (epigastric approach) and $137,98 \pm 6,11$; $143,98 \pm 11,22$; $151,28 \pm 5,23$; $154,76 \pm 19,30$; $158,92 \pm 16,91$; $180,73 \pm 10,25$ (intercostal approach). The accuracy of real time elastography to detect F4 disease was very good, with areas under the receiver operating curve of 0,991 (epigastric approach) and 0,932 (intercostal approach). We didn't found significant differences between mean values of the histogram for near fibrosis stages (Ft F2, F3).

Conclusion: The real time ultrasound elastography is able to detect the patients with liver cirrhosis before they develop visible clinical signs.

NON-INVASIVE EVALUATION METHOD OF THE LIVER FIBROSIS USING REAL-TIME TISSUE ELASTOGRAPHY -USEFULNESS OF JUDGMENT LIVER FIBROSIS STAGE BY LIVER FIBROSIS INDEX (LF INDEX)

Kenji Fujimoto *, Michio Kato, Akiko Tonomura, Norihisa Yada, Chie Tatsumi, Masahide Oshita, Shigeo Wada, Kazuomi Ueshima, Tetsushi Ishida, Tomoko Furuta, Masaru Yamasaki, Masahiko Tsujimoto^J, Mitsuru Motoki, Tsuyoshi Mitake, Shigehiro Kim, Keiji Yamamoto, Tsuyoshi Shiina, Masatoshi Kudo, Norio Hayashi

To evaluate the effectiveness of Real-time Tissue Elastography (RTE) in staging of liver fibrosis non-invasively, we performed RTE on 310 patients with chronic hepatitis C (and/or liver cirrhosis) and 15 healthy volunteers. Nine image features were extracted from each RTE image and a multiple regression analysis was then performed to derive the regression equation. This equation calculates Liver Fibrosis Index (LF Index), which in turn predicts F stage of the liver. LF Index not only correlates highly with the F stage ($r = 0.68$) of the liver fibrosis, but also it shows significant differences in LF Index values ($p < 0.001$) between each stage of the fibrosis. Thus, we can conclude that RTE is a promising method to evaluate the liver fibrosis noninvasively.

Kanzo 2010; 51: 539-541

ULTRASONIC ELASTOGRAPHY IN CLINICAL QUANTITATIVE ASSESSMENT OF FATTY LIVER Yin-Yan Li, Xue-Mei Wang, Yi-Xia Zhang, Guo-Cheng Ou

AIM: To investigate the clinical application of ultrasonic elastography in quantitative assessment of fatty liver grading.

METHODS: A total of 105 patients with fatty liver were divided into mild group ($n = 46$), moderate group ($n = 39$), and severe group ($n = 20$). Forty-five healthy individuals served as a normal control group. All patients who underwent routine ultrasound scan and further ultrasonic elastography were evaluated accordingly to the evaluation standards for ultrasonic elastography. The ratio of surface areas of blue region/total surface area in the desired region was measured.

RESULTS: Ultrasonic elastography technique, in comparison to traditional ultrasound, had a rather high consistence in grading of fatty liver [κ value = $(95.3\% - 63.6\%) / (1\% - 63.6\%) = 0.87$, $P = 0.001$]. The score of ultrasonic elastography increased with the severity of fatty liver with a sensitivity of 97.14% and a specificity of 91.11%. A significant difference was found in the ratio of surface areas of blue regions between different groups ($P < 0.05$).

CONCLUSION: Ultrasonic elastography can be used in quantitative assessment of the severity of fatty liver.

World J Gastroenterol. 2010 Oct 7;16(37):4733-7

NON-INVASIVE EVALUATION OF HEPATIC FIBROSIS FOR TYPE C CHRONIC HEPATITIS.

Tatsumi C, Kudo M, Ueshima K, Kitai S, Ishikawa E, Yada N, Hagiwara S, Inoue T, Minami Y, Chung H, Maekawa K, Fujimoto K, Kato M, Tonomura A, Mitake T, Shiina T.

Department of Gastroenterology and Hepatology, Kinki University School of Medicine, Osaka-Sayama, Japan.

OBJECTIVE: The aim of this study was to investigate liver fibrosis using non-invasive Real-time Tissue Elastography (RTE) and transient elastography (FibroScan) methods.

METHODS: RTE, FibroScan and percutaneous liver biopsy were all performed on patients with chronic liver disease, particularly hepatitis C, to investigate liver fibrosis.

RESULTS: FibroScan and RTE were compared for fibrous liver staging (F stage), which was pathologically classified using liver biopsy. In FibroScan, significant differences were observed between F1/F3 and F2/F4, but no such differences were observed between F1/F2, F2/F3 and F3/F4. In RTE, significant differences were observed between F1/F2, F2/F3 and F2/F4. But for F3/F4, no significant differences were observed.

CONCLUSION: FibroScan and RTE correlated well with F staging of the liver. In particular RTE was more successful than FibroScan in diagnosing the degree of liver fibrosis.

Intervirology. 2010;53(1):76-81. Epub 2010 Jan 5.

[REAL-TIME TISSUE ELASTOGRAPHY IN CHRONIC LIVER DISEASE]

[Article in Japanese]

Morishita S, Hirooka Y, Sato K, Kato Y, Fukuda C, Endo K, Ikeguchi M, Koda M, Suou T.

Department of Pathobiological Science and Technology, School of Health Science, Faculty of Medicine, Tottori University, Yonago 683-8503, Japan.

Abstract

BACKGROUND/AIM: In patients with chronic liver diseases, the histological classification of liver fibrosis is essential for predicting prognosis and selecting appropriate antiviral therapy. This study aimed to determine the usefulness of a new noninvasive method for the assessment of liver fibrosis by using real-time tissue elastography, which can be performed with conventional ultrasound probes.

METHODS: Thirty-nine patients who had liver fibrosis and had undergone liver resection or liver biopsy were included in this study. The surgical specimens obtained were examined to determine the histological stage of liver fibrosis. The strain ratio of subcutaneous fat tissue to liver tissue was calculated. We examined the correlation between the strain ratio and the histological liver fibrosis stage, and compared the utility with various surrogate liver fibrosis markers.

RESULTS: The strain ratio significantly differed with the stage of liver fibrosis, and they had significant correlation (Kruskal-Wallis test: $p < 0.0001$; Spearman's rank correlation, $p < 0.0001$, $r = 0.797$). We identified 5.8 and 3.7 as the cutoff values of strain ratio for the diagnosis of cirrhosis and significant fibrosis. The sensitivity at these values was 92.9% and 81.9% respectively; the specificity, 96.0% and 88.9%; and the areas under the receiver operating characteristic curve (AUROCs), 0.977 and 0.913, respectively. The AUROC was superior to the other surrogate liver fibrosis markers tested.

CONCLUSIONS: Real-time tissue elastography is a useful method for the diagnosis of significant fibrosis and cirrhosis in patients with chronic liver diseases

Rinsho Byori. 2010 Apr;58(4):319-24.

REAL-TIME SONO-ELASTOGRAPHY IN THE DIAGNOSIS OF DIFFUSE LIVER DISEASES.

Gheonea DI, Săftoiu A, Ciurea T, Gorunescu F, Iordache S, Popescu GL, Belciug S, Gorunescu M, Săndulescu L.

Research Center of Gastroenterology and Hepatology, University of Medicine and Pharmacy Craiova, 1 Mai, 66, Craiova 200639, Romania.

AIM: To analyze whether computer-enhanced dynamic analysis of elastography movies is able to better characterize and differentiate between different degrees of liver fibrosis.

METHODS: The study design was prospective. A total of 132 consecutive patients with chronic liver diseases and healthy volunteers were examined by transabdominal ultrasound elastography. All examinations were done by two doctors.

RESULTS: Due to the limitations of the method, we obtained high-quality elastography information in only 73.48% of the patients. The kappa-means clustering method was applied to assess the inter-observer diagnosis variability, which showed good variability values in accordance with the experience of ultrasound examination of every observer. Cohen's kappa test indicated a moderate agreement between the study observers (kappa = 0.4728). Furthermore, we compared the way the two observers clustered the patients, using the test for comparing two proportions (t value, two-sided test). There was no statistically significant difference between the two physicians, regardless of the patients' real status.

CONCLUSION: Transabdominal real-time elastography is certainly a very useful method in depicting liver hardness, although it is incompletely tested in large multicenter studies.

World J Gastroenterol. 2010 Apr 14;16(14):1720-6.

DIAGNOSIS AND ASSESSMENT OF THE STAGE OF HEPATIC FIBROSIS WITH REALTIME ELASTOGRAPHY

C.Ribeiro, L.Catherine, C.Bricout, D.Musset, Hôpital Antoine Bécclère, Clamart - France

Purpose: to evaluate the performance of realtime elastography in diagnosis and stadification of hepatic fibrosis.

Methods and materials: We included in this prospective study 31 consecutive patients examined with a Hitachi EUB-7500 US system with an embedded SonoElastography module.

The final diagnosis was based on the results of liver biopsy, with liver fibrosis quantified according to the Metavir scoring system.

RTE was performed through the right intercostal space in the same time and in the same place as liver biopsy.

Using a specific computer program, various calculations of the elasticity were processed, based on 3 parameters (analysis of centroid numbers, analysis of percentage area, and analysis of the average) and correlated with the stage of fibrosis on histology.

Results: liver biopsy analysis gave these results: 6 F0, 5F1, 7F2, 2 F3 and 5 F4.

Using our specific computer program, no case of fibrosis were classified F0 by realtime elastography. F4 lesions were detected in 80% of cases (a single misclassified lesion on 4). F0 lesions were correctly classified in 84% of cases (a single misclassified lesion on 6).

Patients with fibrosis score F1-F2 were correctly classified in 88% of cases (a single misclassified lesion on 6).

The two F3 lesions were misclassified.

Conclusion: Realtime-Elastography is a simple and non-invasive method for the assessment of liver fibrosis which can be performed during a normal liver ultrasound examination without the need for any additional equipment

By differentiating patients without fibrosis, this technique may avoid unnecessary invasive liver biopsy.

Furthermore, the results showed optimal correlation between the elasticity to be described by our specific computer program with the stage of fibrosis on histology.

Radiological Society of North America 95th Scientific Assembly and Annual Meeting November 29th – December 4th, 2009, Chicago, USA

ROLE OF ULTRASOUND ELASTOGRAPHY IN THE DIAGNOSIS AND STAGING OF LIVER FIBROSIS

C RIBEIRO, L CATHERINE, C BRICOUT, D MUSSET
CLAMART - FRANCE
(Translated from French)

Purpose: To evaluate the performance of real-time tissue elastography (HI-RTE) in the diagnosis and staging of liver fibrosis

Materials and method: The liver HI-RTE mode (system Hitachi EUB-7500) was evaluated in 31 patients undergoing liver biopsy. The HI-RTE study and the liver biopsy was performed at the same consultation and from the same location in the liver. The stage of liver fibrosis was estimated by combining 3 parameters obtained by analysis of the HI-RTE liver image (mean, number of centroids and percentage of area). The results were compared to the histology from the percutaneous biopsy classified according to the Metavir score (from F0 to F4). There were 6 failed examinations (n = 25).

Results: The results of the analysis were as follows: 6 F0, 5 F1, 7 F2, 2 F3 and 5 F4. Using the specific combined analysis, no patient was classified as F0 by HI-RTE. The F4 lesions were seen in 80% of cases (1 wrongly classified on 4 using our analysis). The F0 lesions were correctly classified in 84% of cases (1 wrongly classified on 6). The F1 – F2 lesions were correct in 88% of cases (1 wrongly classified). The 2 F3 lesions were wrongly classified.

Conclusion: In our series of patients using a combined analysis, HI-RTE appears to be a useful diagnostic tool that can differentiate patients without fibrosis and thereby reduce the number of unnecessary biopsies. HI-RTE also showed a good positive predictive value for staging liver fibrosis. The main limitation of our study is the small number of patients which were included which prevented us from drawing definite conclusions concerning the F1-F2 and F3 lesions.

JFR 2009, Paris, October 16th – 20th

REAL-TIME TISSUE ELASTOGRAPHY VERSUS FIBROSCAN FOR NONINVASIVE ASSESSMENT OF LIVER FIBROSIS IN CHRONIC LIVER DISEASE

M. Friedrich-Rust, A. Schwarz, M. Ong, V. Dries, P. Schirmacher, E. Herrmann, P. Samaras, J. Bojunga, R. M. Bohle, S. Zeuzem, C. Sarrazin

Abstract

Purpose: Transient elastography (FibroScan, [TE]) and serum fibrosis markers such as the FibroTest (FT) are established methods for the noninvasive staging of liver fibrosis. A study using real-time elastography (HI-RTE), which is integrated in a conventional ultrasound system, was recently published with comparable results to transient elastography. The aim of the present study was to validate real-time elastography using the formulas calculated in previous studies and to compare the results to transient elastography and FibroTest for the noninvasive assessment of liver fibrosis.

Materials and Methods: One hundred and thirty-four patients with chronic liver disease and either histological assessment of liver fibrosis (n = 112) or proven liver cirrhosis (n = 22) were included in the study. All patients received TE, HIRTE, and biochemical evaluation on the same day as presentation.

The calculation of the elasticity score of real-time elastography was performed in accordance with the two previously published studies.

Results: The Spearman correlation coefficient between transient elastography, real-time elastography and FibroTest with the histological Chevallier score was statistically significant with 0.78, 0.34, and 0.67, respectively ($p < 0.01$). The diagnostic accuracy expressed as areas under ROC curves was 0.84, 0.69 and 0.85 for the diagnosis of significant fibrosis ($F \geq 2$), and 0.97, 0.65, and 0.83 for the diagnosis of cirrhosis, respectively.

Conclusion: Real-time elastography in its present form cannot replace transient elastography for noninvasive assessment of liver fibrosis.

Ultraschall in Med 2009; 30: 478 - 484

THE ROLE OF REAL-TIME ELASTOGRAPHY IN THE NON-INVASIVE ASSESSMENT OF FIBROSIS IN DIFFUSE HEPATOPATHIES.

Dan Ionuț Gheonea*, Adrian Săftoiu, Florin Gorunescu, Marina Gorunescu, Tudorel Ciurea

*Gastroenterology Department, University of Medicine and Pharmacy Craiova, Romania

Aim: Ultrasound elastography was recently reported to offer supplemental information that appears to yield a better characterization of liver tissue [1]. The principle of real-time elastography (RTE) is that tissue compression produces displacement within the tissue and that the strain is smaller in harder tissue as compared to softer tissue [2]. The aim of the study was to analyze whether computer-enhanced dynamic analysis of RTE movies is able to better characterize the degree of fibrosis in chronic hepatic diseases.

Methods: We included in this prospective study 97 consecutive patients examined in the Research Centre of Gastroenterology and Hepatology Craiova by RTE, with a Hitachi 8500 US system with an embedded SonoElastography module. Patients with alcoholic fatty liver disease ($n=21$), viral B, C or B+D hepatitis ($n=26$), cirrhosis ($n=29$) and healthy volunteers ($n=21$) were examined. RTE was performed through the right intercostal space, during breath holding at end-expiration phase (Figure 1). Two examinations consisting of three distinct ten second elastography movies were consecutively recorded by two different operators, blinded to each other and to the liver biopsy information. Each acquired elastography movie was subject to computer-enhanced dynamic analysis using a public domain Java-based image processing tool (ImageJ). The final diagnosis was based on the results of liver biopsy, with liver fibrosis quantified according to the Metavir scoring system.

Results: Due to the limitations of the method, we obtained high-quality elastography information in only 73.48% of the patients. The k-means clustering method was applied to assess the inter-observer diagnosis variability, showing good variability values in concordance with the experience in ultrasound examination of every observer. Cohen's kappa test indicated a moderate agreement between the study observers ($\kappa=0.4728$). Furthermore, we compared the way the two observers have clustered the patients, using the test for comparing two proportions (t-value, two-sided test). Thus, we obtained that there is no statistical significant difference ($p=0.54, 0.85, 0.81$ and 0.78 respectively) between the two physicians, regardless of the patients' real status.

Conclusions: Real time elastography is a new and promising method for the characterization of liver fibrosis in chronic hepatic diseases, but it should be compared with other non-invasive markers, transient elastography and liver biopsy results in large multi-centric studies with improved methodology.

References:

- [1] Friedrich-Rust M, Ong MF, Herrmann E, Dries V, Samaras P, Zeuzem S, Sarrazin C, Real-time elastography for noninvasive assessment of liver fibrosis in chronic viral hepatitis, *AJR Am J Roentgenol.*, 188:758–764, 2007.
- [2] Saftoiu A, Gheonea DI, Ciurea T, Hue histogram analysis of real-time elastography images for noninvasive assessment of liver fibrosis, *AJR Am J Roentgenol.*, 189:W232–233, 2007.

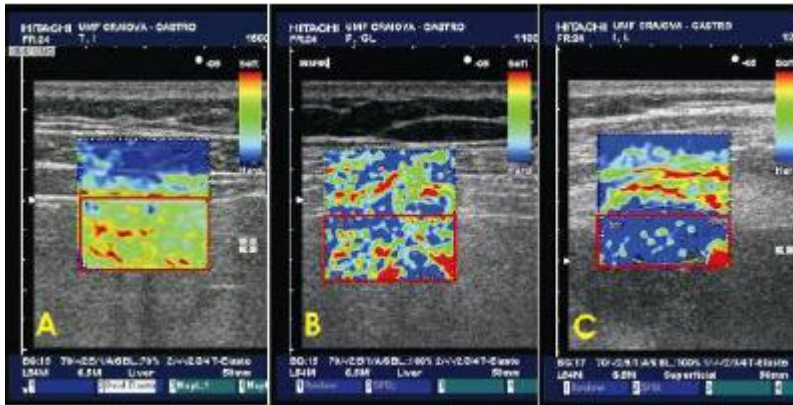


Figure 1: Comparative elastography aspects of (A) alcoholic fatty liver disease, (B) chronic viral hepatitis and (C) cirrhosis.

Eighth International Conference on the Ultrasonic Measurement and Imaging of Tissue Elasticity, September 14 – 17, 2009, Vlissingen, The Netherlands

ANALYSIS OF STRAIN PATTERNS OF COMMON LIVER TUMORS USING REAL-TIME TISSUE ELASTOGRAPHY

Dr Katsuhiko Fukuda, Mr Masami Mori, Ms Mikako Koma, PL General Hospital, Japan

Real-time Tissue Elastography (RTE) is a newly developed, noninvasive method that enables to visualize the elasticity of target tissue or tumors. It has been proved to be very useful for the assessment of mammary or thyroid tumors. Here, we performed RTE and assessed its diagnostic usefulness for common liver tumors.

Methods: Subjects were 47 liver tumors including 14 HCCs, 12 metastatic liver tumors, and 21 hemangiomas. We performed RTE as follows; using Hitachi EUB-8500 and EUP-L52 probe, we compressed the liver surface slightly with the probe to induce appropriate strain to liver tumors and obtained their color strain images. Then, we classified the obtained strain images into five groups in contrast to the surrounding liver: category 1 (even strain pattern), category 2 (less strain area in the tumor < 50%), category 3 (less strain area = about 50%), category 4 (50% < less strain area < 90%), and category 5 (less strain area > 90%), respectively.

Results: Of 14 HCCs, twelve were classified as category 4. Of 12 metastatic liver tumors, eleven were classified as category 4 or 5. Of 21 hemangiomas, 17 were classified as category 1 or 2. RTE revealed that HCC or metastatic liver tumors had less strain than the surrounding liver whereas most hemangiomas did not.

Conclusion: We found that common liver tumors had their own strain patterns which could help to make a differential diagnosis. RTE is considered to be a noninvasive and promising method that provides us useful information regarding liver tumor strain.

12th World Congress of the World Federation for Ultrasound in Medicine and Biology, 30th August – 3rd September 2009, Sydney, Australia

EVALUATION OF HEPATIC FIBROSIS IN CHRONIC HEPATITIS C USING REAL-TIME TISSUE ELASTOGRAPHY

Mr Masami Mori, Dr Katsuhiko Fukuda, Ms Mikako Koma, Ms Akiko Tonomura, Mr Tsuyoshi Mitake
Department of Clinical Laboratory, PL General Hospital, Japan
Ultrasound System Division, Hitachi Medical Corporation, Japan

Hepatic fibrosis is deeply correlated with progression of chronic hepatitis C (CH-C) and hepatocarcinogenesis. Thus, it is very important to evaluate the degree of fibrosis in CH-C precisely, if possible, noninvasively. Real-time Tissue Elastography (RTE: Hitachi Medical Co., Japan) is a recently developed noninvasive method for evaluating the elasticity of the target tissue as a visual color image, and found to be very useful for screening of breast cancer. Here, we studied hepatic

fibrosis in CH-C using this novel method and assessed its performance in comparison with surrogate fibrosis serum markers.

Method: Subjects were 98 CH-C patients including 77 CH and 21 LC, and 10 healthy volunteers (V). We performed RTE using Hitachi EUB-8500 and EUP-L52 linear probe, scanned liver in the right intercostal region with a slight compression, obtained color strain images and analyzed them quantitatively by an image analysis software. We, then, studied the correlation between the obtained various strain parameters (mean and standard deviation of relative strain, and area of hard region) and serum fibrosis markers (platelet count and serum hyaluronic acid).

Results: RTE color strain image varied from a green (soft) dominant pattern to a blue (hard) dominant pattern in according to the progression of hepatic fibrosis.

Strain parameters:

	Mean	SD	Hard area
CH	122.57±19.6	47.86±9.9	15.61±11.5
LC	76.88±20.1	59.73±10.1	49.06±15.1
V	151.63±11.5	38.07±6.5	1.48±1.5

The obtained strain parameters were well correlated with surrogate fibrosis serum markers.

Conclusion: We conclude that RTE is a promising noninvasive tool for evaluating hepatic fibrosis in chronic liver diseases.

12th World Congress of the World Federation for Ultrasound in Medicine and Biology, 30th August – 3^d September 2009, Sydney, Australia

IMAGE ANALYSIS OF REAL-TIME TISSUE ELASTOGRAPHY FOR EVALUATION OF LIVER FIBROSIS PROGRESSION

Akiko Tonomura, Tsuyoshi Mitake, Ultrasound Systems Division, Hitachi Medical Corporation, Japan; Tsuyoshi Shiina, Graduate School of Medicine, Human Health Science, Kyoto University, Japan; Kenji Fujimoto, Michio Kato, Department of Internal Medicine, Minami Wakayama Medical Center, Japan; Chie Tatsumi, Masatoshi Kudo, Department of Gastroenterology and Hepatology, Kinki University School of Medicine, Japan

Objective: Real-time Tissue Elastography(RTE) is a new ultrasound mode developed for visualizing tissue hardness and softness. Recently, RTE has been extended to study liver fibrosis and reported that RTE image becomes patchy as fibrosis progresses. However, it is difficult to evaluate fibrosis progression visually from the patchy pattern quantitatively. In this study, we will present a method to evaluate liver fibrosis quantitatively using features of RTE image. This technique would significantly reduce interobserver variability in studying liver fibrosis.

Methods: From the RTE images, where strain-image in color is overlaid upon a B-mode image, various RTE parameters, such as mean of relative strain value(MEAN), standard deviation of relative strain value(SD), area of low strain region(AREA) and complexity of low strain region(COMP) were calculated. Then, multiple regression analysis was performed to derive regression equation. With this equation, RTE fibrosis value was calculated and compared with the fibrosis stage. We have studied 21 patients(F1:4, F2:8, F3:5, F4:4) with diffuse liver disease. All data were collected at Minami Wakayama Medical Center with HITACHI HI VISION 900 and EUP-L52 linear probe(3-7MHz).

Results: Correlation coefficient of MEAN, SD, AREA, and COMP were -0.603, 0.355, 0.569, and 0.436 respectively. Multiple regression analysis performed with these 4 features yielded a RTE fibrosis value, and it highly correlated with the fibrosis stage($r=0.751$).

Conclusions: This quantitative technique would increase the confidence in the evaluation of fibrosis progression and will also reduce interobserver variability. Thus RTE would greatly benefit in the study of liver fibrosis progression.

EVALUATION AND COMPARATIVE ANALYSIS OF LIVER FIBROSIS NON-INVASIVE DIAGNOSTIC METHODS IN PATIENTS WITH CHRONIC HEPATITIS C AND B: DOPPLER ULTRASONOGRAPHY, ELASTOGRAPHY AND FIBROTEST

Dr Chavdar Pavlov, Oxana Konovalova, Dmitrii Glushenkov, Vsevolod Zolotarevsky, Prof Vladimir Ivashkin
I.M. Sechenov Moscow Medical Academy, Russia

Objective: The aim of this investigation was the estimation of diagnostic accuracy and to carry out comparative analysis of data received by Doppler ultrasonography (DUS), elastography and FibroTest for evaluation of liver fibrosis stage for patients with CHC and CHB.

Methods: 200 patients, age 35.6±10.9 years were investigated clinically at Vasilenko Clinic. Hospitalized patients with diagnosis of chronic hepatitis - 75% (HCVRNA +) and 25% (HBVDNA +) were divided in three groups, each investigated using one of three methods: DUS, elastography and FibroTest (100, 50 and 50 patients, respectively). Splenic artery pulsatility index (SAPI) and mean velocity of portal vein blood flow (MVPV) were determined by Doppler ultrasonography. The results of non-invasive methods were compared to data of fibrosis according to METAVIR. Taking into account the stage of fibrosis, all patients were separated into groups (F0-F1) and (F2-F4). The statistical data was processed in SPSS 16.0.

Results: The comparative analysis of results has revealed the informativity of the studied methods: Elastography (AUROC - 0.888; 95%-CI - 0.815-0.960; p <0.001), FibroTest (AUROC - 0.884; 95%-CI - 0.824-0.944; p <0.001), DUS SAPI (AUROC - 0.843; 95%-CI - 0.755-0.930; p <0.001), DUS MVPV (AUROC - 0.695; 95%-CI - 0.591-0.820; p =0.001).

Conclusions: Data of DUS, elastography and FibroTest is highly reliable, informative and allows to carry out non-invasive diagnostics of severe (F2-F4) liver fibrosis for patients with CHC and CHB. High level of accuracy comparing to the traditional needle liver biopsy allows recommending the investigated methods in clinical practice as independent screening methods.

DOPPLER ULTRASONOGRAPHY, FIBROTEST AND ELASTOGRAPHY IN NON-INVASIVE DIAGNOSTICS OF LIVER CIRRHOSIS IN PATIENTS WITH CHRONIC HEPATITES B AND C

Dr Chavdar Pavlov, Oxana Konovalova Dmitrii Glushenkov, Vsevolod Zolotarevsky, Prof Vladimir Ivashkin

Objective: Evaluation of information value and comparative analysis of diagnostic accuracy of Doppler ultrasonography, elastography and FibroTest in non-invasive diagnostics of liver cirrhosis for patients with CHC and CHB.

Methods: Overall 200 patients, mean age 35.6±10.9 years were investigated. Patients were represented by three groups, each of them has been studied using one of three methods: Doppler ultrasonography, elastography and FibroTest (100, 50 and 50 patients, respectively). Patients were hospitalized at Vasilenko clinic with diagnosis of chronic hepatitis - 75 % (HCVRNA +) and 25 % (HBVDNA +). The obtained results were compared to the data according to METAVIR. Splenic artery pulsatility index (SAPI) and mean velocity of portal vein blood flow (MVPV) were determined by Doppler ultrasonography. Then patients were divided in two groups depending on the stage of liver fibrosis: first — with F0-F3 fibrosis stage and second — with liver cirrhosis (F4). Statistical processing of results was performed by SPSS 16.0.

Results: The comparative analysis of results has revealed the informativity of the studied methods: Elastography (AUROC - 0.963; 95%-CI: 0.929-0.997; p<0.001), FibroTest (AUROC - 0.950; 95%-CI: 0.894-1.005; p<0.001), DUS SAPI (AUROC - 0.912; 95%-CI: 0.785-0.954; p<0.001), DUS MVPV (AUROC - 0.803; 95%-CI: 0.690-0.946; p<0.001).

Conclusions: DUS, elastography and FibroTest scores are characterized by high informative value and reliably represent development of liver cirrhosis in CHC and CHB patients. High diagnostic accuracy of these methods allows recommending them as screening diagnostics tests to reveal patients with F4 liver fibrosis who have no clinical signs of cirrhosis.

12th World Congress of the World Federation for Ultrasound in Medicine and Biology, 30th August – 3^d September 2009, Sydney, Australia

ASSESSMENT OF LIVER FIBROSIS BY REAL TIME SONOELASTOGRAPHY (HITACHI) AS COMPARED TO LIVER BIOPSY AND TRANSIENT ELASTOGRAPHY

Alina Popescu, Ioan Sporea, Mircea Focsa, Viviana Sandra, Veronica Ruta, Alexandra Deleanu, Mirela Danila, Roxana Sirlu

Department of Gastroenterology and Hepatology, University of Medicine and Pharmacy Timisoara, Romania, Romania

Aim: to compare real time sonoelastographic (RT-SE) evaluation of liver fibrosis with two well established methods, liver biopsy (LB) and transient elastography (TE).

Material and method: Our study included 44 patients: 9 healthy volunteers; 30 patients with chronic hepatitis who underwent LB; and 6 with cirrhosis.

All the patients were evaluated by:

- TE (FibroScan®, EchoSens): a median value of liver stiffness was obtained after 10 measurements (kPa).

- RT-SE (Hitachi HiVision 900 System), using a convex probe (2.5-5MHz) and a linear probe (6.5-13MHz). Five images were obtained with each probe and were processed by means of ImageJ application. We separated the RGB color channels and we calculated the ratio between the blue colored areas (stiff tissue encoded in blue) and the total elastographic area (blue ratio).

We assessed the correlation between the data from RTSE and those obtained by LB and TE.

Results: A strong direct correlation was observed between TE and liver fibrosis (Spearman's $\rho=0.871$). The mean values for the blue ratio were: 11.1 ± 6.3 for the convex probe and 18.0 ± 8.9 for the linear probe ($p=0.458$). For the convex probe, only a weak direct correlation was found between RT-SE and LB ($\rho=0.306$) or TE ($\rho=0.216$). No correlation was found between RT-SE evaluations made with the linear probe and LB, nor with TE.

Conclusion: As compared with LB or TE, our processing technique of RT-SE images did not result in expected information regarding the liver fibrosis.

12th World Congress of the World Federation for Ultrasound in Medicine and Biology, 30th August – 3^d September 2009, Sydney, Australia

EVALUATION OF LIVER FIBROSIS IN DIFFUSE LIVER DISEASE USING REAL-TIME TISSUE ELASTOGRAPHY

Kenji Fujimoto, Chie Tatsumi, Kazuomi Ueshima, Tsuyoshi Shiina, Akiko Tonomura, Tsuyoshi Mitake, Keiji Yamamoto, Masatoshi Kudo, Michio Kato

[Objective] Real-time Tissue Elastography (RTE) is developed for visualizing the tissue hardness/softness by using ultrasound. We have been investigating its ability of evaluating fibrosis in diffuse liver disease. Recently, newly developed low frequency probe (EUP-L52) has been applied to RTE, and a patient who had difficulty of visualizing RTE image for the reason of low penetration such as obesity has been improved. In this study, multiple linear regression analysis was performed using several features of RTE image to estimate the RTE fibrosis value, and compared with the fibrosis stage to evaluate the clinical usefulness of RTE.

[Material and Method] 26 patients with chronic hepatitis C or liver cirrhosis diagnosed by liver biopsy, and 6 healthy volunteers were examined in this study. The indicated stages of fibrosis were F0 in 2 patients, F1 in 6 patients, F2 in 8 patients, F3 in 6 patients, and F4 in 4 patients. RTE were performed with HITACHI HI VISION 900 and EUP-L52 linear probe (3-7MHz). Scan was performed

through the right intercostal space to observe right lobe. Probe was slightly held to detect the strain by heartbeat. All RTE images were transferred to an external PC, and analyzed with prototype image analysis software. Color data inside the ROI were converted to relative strain value, and features of RTE image such as mean of relative strain value (MEAN), standard deviation of relative strain value (STD), area of blue region (AREA), and complexity of blue region (COM) were calculated. Then, multiple regression analysis was performed with features of RTE image and fibrosis stage.

[Results] Features of RTE image were highly correlated with fibrosis stage. Correlation coefficient of MEAN, STD, AREA, and COM were $r=-0.604$, 0.593 , 0.592 , and 0.578 . With these 4 parameters, multiple regression analysis was performed and derived the regression equation, which significantly fit with the data. RTE fibrosis value was calculated from this equation and had high correlation with fibrosis stage ($r=0.729$).

[Conclusion] As a result of having analyzed RTE quantitatively, the quantity of characteristic reflected staging well. RTE is particularly useful as the modality that can grasp improvement of the fibrosis by a hepatitis diagnosis and the treatment non-invasively.

“HI VISION” is a registered trademark of Hitachi Medical Corporation in U.S.A.

Digestive Disease Week, May 30th – June 4th, 2009, Chicago, USA, M1774

REAL-TIME SONOELASTOGRAPHY - A NEW APPLICATION IN THE FIELD OF LIVER DISEASE

Liana Gheorghe, Speranta Iacob, Cristian Gheorghe
Hepatology Department, Center of Gastroenterology and Hepatology, Fundeni Clinical Institute,
“Carol Davila” University of Medicine and Pharmacy, Bucharest, Romania

Ultrasound elastography is a new imaging technique that allows a noninvasive estimation and imaging of tissue elasticity distribution within biological tissues using conventional real-time ultrasound equipment with modified software. Elastography has been reported to be useful for differentiation and characterization of various malignant tumors, such as breast, prostate, thyroid, pancreas, lymph nodes, gastrointestinal stromal tumors, hepatocellular carcinoma and liver metastasis. Transient and, more recently, real-time elastography has been proved to be useful for noninvasive assessment of liver fibrosis in patients with diffuse liver diseases. Elasticity imaging promises to make an important contribution to ultrasound practice.

J Gastrointest Liver Dis, December 2008 Vol. 17 No 4, 469-474

REAL-TIME ELASTOGRAPHY - A PILOT STUDY FOR NON-INVASIVE DETECTION OF SMALL HEPATOCELLULAR CARCINOMA IN CIRRHOTIC PATIENTS

Liana Gheorghe, Speranta Iacob, Razvan Iacob, Gabriel Becheanu, Mona Dumbrava, Cristian Gheorghe, Iulia I. Simionov, Ioana Lupescu, Irinel Popescu

BACKGROUND: Ultrasound (US) screening for hepatocellular carcinoma (HCC) is worthwhile because early detection is the only approach to improve outcome. Small nodules (<3 cm) detected on US in cirrhotics represent the most challenging category for noninvasive diagnosis of HCC. By assessing tissue elasticity distribution, real-time sonoelastography may represent a reliable method for differentiating between benign and malignant lesions in this setting.

AIM: To evaluate realtime sonoelastography as a noninvasive tool for the detection of small HCC nodules in cirrhotic patients.

METHODS: Nineteen cirrhotic patients with small nodules (1-3 cm) were evaluated with real-time elastography (SonoElastography mode, HITACHI EUB-6500); the mean intensity of colors red, blue, green were measured using a semi-quantitative method. Analysis of histograms for each color of the sonoelastography images was performed for quantifying the elasticity of nodule tissue comparative with cirrhotic liver tissue. In order to investigate the predictive role of sonoelastography for diagnosis of HCC, the c-statistic parameter was used. The final diagnosis of HCC was obtained by liver biopsy within the nodule, surgical pathology or at least 6 months follow-up.
RESULTS: There were analyzed 213 sonoelastography images from 19 patients (12 men; 7 women)

who underwent transabdominal ultrasound. The mean age was 58 ± 12.9 years and 73.5% patients were in Child-Pugh class A, 10.5% class B and 16% class C. The histologic diagnosis found trabecular and microglandular aspects of moderate differentiated carcinoma in 8 patients and well differentiated carcinoma in 2 patients. The c-statistic for green color is 0.8, a cut-off value of <106.5 being diagnostic for HCC with a specificity of 84%, sensitivity 58%, positive predictive value 81% and negative predictive value 62%. Blue color proved to be an excellent diagnostic tool for HCC (c-statistic=0.95); for a cut-off value >121.4 , the specificity was 86%, sensitivity 91%, positive predictive value 89% and negative predictive value 89.7%. The kappa reliability test was 0.8 for concordance between blue criteria of HCC and histologic diagnosis. Combined criteria for green and blue color have a diagnostic accuracy for HCC of 82.3%.

CONCLUSION: US real-time elastography is a promising method for screening and non-invasive diagnosis of HCC. It allows to distinguish between HCC nodules and regenerative cirrhotic macronodules, being an useful tool for early referral of Child-Pugh class A cirrhotic patients for liver transplantation or curative resection.

Digestive Disease Week, May 17th – 22nd, 2008, San Diego, USA T1947
American Association for the Study of Liver Disease, 2008, A-827

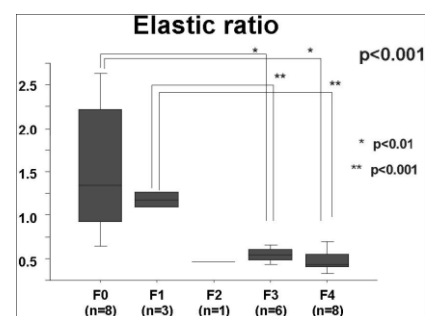
REAL-TIME ELASTOGRAPHY FOR NONINVASIVE DIAGNOSIS OF LIVER FIBROSIS

Mami Kanamoto, Mitsuo Shimada, Toru Ikegami, Satoru Imura, Yuji Morine, Tetsuya Ikemoto, Hiroki Mori, Jun Hanaoka, Koji Sugimoto, Takuya Tokunaga

INTRODUCTION Accurate evaluation of liver fibrosis has significant importance in following up patients with viral or nonviral chronic hepatitis. Although percutaneous needle liver biopsy is still the gold standard for such assessments, it is an invasive procedure with possible undesirable complications including serious bleeding events. In the current study, we have focused on a new mode of sonogram “Real-time Elastography”, which can show tissue elasticity up on the image, and express the elasticity numerically. The aim of this study was to evaluate the usefulness of “Real-time Elastography” in the assessment of liver fibrosis.

MATERIALS AND METHODS Twenty six patients, who had been underwent intra-operative liver biopsy or hepatectomy between August in 2005 and November in 2007, were included in this study. Hepatic elasticity was measured using Real-time Elastography (EUB-8500, Hitachi Medical Systems). In evaluation of liver fibrosis, we calculated elastic ratio of the liver for the subcutaneous tissue. We examined correlation of the elastic ratio with histological fibrosis staging. In addition, hyaluronic acid and type IV collagen levels were included in the analysis.

RESULTS As liver fibrosis staging advanced, elastic ratio was lower. There was correlation between the elastic ratio and the histological fibrosis stages (F0: F1: F2: F3: F4= 1.53: 1.08: 0.46: 0.54: 0.48; $p < 0.001$). The elastic ratio of F3 was lower than that of F0 and F1. And the elastic ratio of F4 was especially lower than that of F0 and F1. Moreover, there was correlation between the histological fibrosis stages and hyaluronic acid levels (F0: F1: F2: F3: F4= 38: 80: 89: 134: 228; $p < 0.001$). On the other hand, there was no correlation between the fibrosis stages and type IV collagen levels.



CONCLUSION Real-time elastography is a new and promising sonography-based noninvasive methods for the assessment of liver fibrosis.

Digestive Disease Week, May 17th – 22nd, 2008, San Diego, USA T1951

INTRA-OPERATIVE APPLICATION OF REAL-TIME TISSUE ELASTOGRAPHY FOR THE DIAGNOSIS OF LIVER TUMOURS

Koichi Kato, Hiroyuki Sugimoto, Naohito Kanazumi, Shuji Nomoto, Shin Takeda and Akimasa Nakao
Department of Surgery II, Nagoya University Graduate School of Medicine, Nagoya, Japan

Objective: Real-time tissue elastography (RTE) has made it possible to visualize tissue elasticity. The aim of this study was to evaluate the usefulness of RTE for the differential diagnosis of liver tumours during surgical exploration.

Methods: Fiftyfive liver tumours in 44 patients were examined with RTE, concomitant with routine intra-operative ultrasonography. Elasticity images were classified into four types, from type A (even strain) to type D (no strain), according to the distribution and the degree of the strain contrasted with that of the surrounding liver [elasticity type of liver tumour (ETLT)]. We evaluated the consistency of the findings of RTE with the pathological diagnosis as a reference standard.

Results: All malignant lesions showed various degrees of strain reduction in the tumour tissue. Twentyone of 22 hepatocellular carcinomas (HCCs) were classified as type B with a sensitivity of 95.5%, a specificity of 90.9% and an accuracy of 92.7%, while all 24 metastatic adenocarcinomas were classified as either type C or type D with a sensitivity of 100%, a specificity of 80.6% and an accuracy of 89.1%.

Conclusion: Application of RTE in surgical exploration provided significant information about the elasticity of liver tumours. RTE, using a new criterion, ETLT, enabled us to distinguish rather accurately between two common malignancies: HCC and metastatic adenocarcinoma.

Liver International. 2008;28(9):1264-1271

EARLY AND NON-INVASIVE DIAGNOSIS OF SMALL HEPATOCELLULAR CARCINOMA USING REAL-TIME ELASTOGRAPHY

Gheorghe L, Iacob S, Lupescu I, Becheanu G, Dumbrava M, Iacob R, Gheorghe C, Popescu I
Fundeni Clinical Institute

Background and aim: Small nodules (< 3 cm) detected on ultrasound (US) in cirrhotics represent the most challenging category for noninvasive diagnosis of hepatocellular carcinoma (HCC). The study aim was to evaluate real-time sonoelastography as a noninvasive tool for the detection of small HCC nodules in cirrhotic patients.

Methods: Twenty eight cirrhotic patients with small nodules (1- 3 cm) were evaluated with real-time elastography (SonoElastography mode. HITACHI EUB-6500); the mean intensity of colors red, blue, green were measured using a semi-quantitative method. Analysis of histograms for each color of the sonoelastography images was performed for quantifying the elasticity of nodule tissue comparative with cirrhotic liver tissue. In order to investigate the predictive role of sonoelastography for diagnosis of HCC. the c-statistic parameter was used. The final diagnosis of HCC was obtained by liver biopsy within the nodule, surgical pathology or at least 6 months follow-up.

Results: There were analyzed 303 sonoelastography images from 28 patients (17 men; 11 women) who underwent transabdominal ultrasound. The mean age was 57.2 ± 11.1 years and 75% patients were in Child-Pugh class A, 14.2 % class Band 10.8 % class C. The c-statistic for green color is 0.76, a cut-off value of < 129.3 being diagnostic for HCC with a specificity of 82.5%, sensitivity 58.3%, positive predictive value 80.6 % and negative predictive value 61.4 %. Blue color proved to be an excellent diagnostic tool for HCC (c-statistic = 0.97); for a cut-off value > 121.4, the specificity was 86.6%, sensitivity 96%, positive predictive value 93.8% and negative predictive value 91.2%.

Conclusion: US realtime elastography is a promising method for screening and non-invasive diagnosis of HCC. It allows, to distinguish between HCC nodules and regenerative' cirrhotic macronodules. being an useful tool for referral of Child-Pugh class A cirrhotic patients for liver transplantation or curative resection.

Ultraschall in Med, 2008, suppl 1, PP1.16

XXth Congress of European Federation of Societies for Ultrasound in Medicine and Biology/XIth Romanian Conference of Ultrasound in medicine and Biology, May 31 – June 3 2008, Timisoara, Romania.

THE ROLE OF REAL-TIME ELASTOGRAPHY IN THE NON-INVASIVE ASSESSMENT OF FIBROSIS IN DIFFUSE HEPATOPATHIES

Gheonea DI¹, Saftoiu A¹, Ciurea T¹, Gorunescu F², Iordache S¹, Popescu GL³, Gorunescu M²,
¹Research Centre in Gastroenterology and Hepatology, UMF Craiova; ²Biostatistics Department, UMF Craiova; ³IT Department, UMF Craiova

Aim: Ultrasound elastography was recently reported to offer supplemental information that appears to yield a better characterization of liver tissue. The principle of real-time elastography (RTE) is that tissue compression produces displacement within the tissue and that the strain is smaller in harder tissue as compared to softer tissue. The aim of the study was to analyze whether computer-enhanced dynamic analysis of RTE movies is able to better characterize the degree of fibrosis in chronic hepatic diseases.

Material and methods: We included in this prospective study 97 consecutive patients examined in the Research Centre of Gastroenterology and Hepatology Craiova by RTE, with a Hitachi 8500 US system with an embedded SonoElastography module. Patients with alcoholic fatty liver disease (n = 21), viral B, C or B+D hepatitis (n = 26), cirrhosis (n = 29) and healthy volunteers (n = 21) were examined. RTE was performed through the right intercostal space, during breath holding at end-expiration phase. Two examinations consisting in three distinct ten seconds elastography movies were consecutively recorded by two different operators, blinded to each other and to the liver biopsy information. Each acquired elastography movie was subject to computer-enhanced dynamic analysis using a public domain Java-based image processing tool (ImageJ). The final diagnosis was based on the results of liver biopsy, with liver fibrosis quantified according to the Metavir scoring system.

Results: Using dynamic hue histogram analysis we were able to quantify the degree of liver elasticity inside a defined region of interest located at the periphery of the right liver lobe. The correlation between the mean elasticity values calculated by hue histogram analysis on average images and the degree of histologic fibrosis stage was statistically significant. Furthermore, we have obtained good intra- and inter-observer variability values, with kappa values between 0.41- 0.60, indicating moderate agreement. The use of neural networks has also increased the discriminative ability of the method in order to accurately differentiate between liver fibrosis degrees.

Conclusion: Real time elastography is a new and promising method for the characterization of liver fibrosis in chronic hepatic diseases but it should be compared with other non-invasive markers, transient elastography and liver biopsy results in large multicentric studies with improved methodology.

Young Investigators Award

Ultraschall in Med, 2008, suppl 1, OP17.1

XXth Congress of European Federation of Societies for Ultrasound in Medicine and Biology/XIth Romanian Conference of Ultrasound in medicine and Biology, May 31 – June 3 2008, Timisoara, Romania.

DYNAMIC HUE HISTOGRAM ANALYSIS OF REAL-TIME ELASTOGRAPHY FOR NON-INVASIVE ASSESSMENT OF LIVER FIBROSIS

D. Gheonea¹, A. Saftoiu¹, T. Ciurea¹, G. Popescu², A. Iordache², F. Gorunescu³, I. Rogoveanu⁴, S. Iordache⁴. ¹ Gastroenterology Department, ² IT Center, ³ Biostatistics Department, ⁴ Internal Medicine Department, University of Medicine and Pharmacy, Craiova, Romania

INTRODUCTION: Sono-elastography is a recent imaging method used for the realtime visualization of tissue elasticity. The method reveals the physical properties of the tissue, by characterizing the difference of hardness between diseased tissue and normal tissue. The principle of elastography is that tissue compression produces strain (displacement) within the tissue and that the strain is smaller in harder tissue as compared to softer tissue.

AIMS & METHODS: The study design was prospective. A total of 45 consecutive patients with alcoholic fatty liver disease (n = 7), viral B or C hepatitis (n = 18), cirrhosis (n = 20) and 20 healthy volunteers were examined by real time elastography with a Hitachi 8500 US system with an embedded SonoElastography module. Realtime sonoelastography was performed through the right intercostal space, during breath holding at end-expiration phase. Two examinations consisting in

three distinct elastography movies were consecutively recorded by two different operators, blinded to each other and to the liver biopsy information. Each acquired elastography movie was subject to computer-enhanced dynamic analysis using a public domain Java-based image processing tool (ImageJ). The final diagnosis was based on the results of liver biopsy, with liver fibrosis quantified according to the METAVIR scoring system. **RESULTS:** Patients diagnosed with alcoholic fatty liver disease, chronic viral hepatitis and liver cirrhosis were prospectively included, with a total number of 65 cases examined by real-time sonoelastography. By using dynamic hue histogram analysis we were able to quantify the degree of liver elasticity inside a defined region of interest located at the periphery of the right liver lobe. The correlation between the mean elasticity values calculated by hue histogram analysis on average images and the degree of histologic fibrosis stage was statistically significant ($p < 0.05$). Moreover, the diagnostic accuracy of real-time sono-elastography was also estimated by using receiver operating characteristic (ROC) analysis.

CONCLUSION: Real time elastography is a new and promising method for the characterization of liver fibrosis in chronic hepatic diseases. Prospective studies, with blinded comparisons and multicentric design should aim to compare sonoelastography with other non-invasive methods for the assessment of liver fibrosis (including Fibroscan and magnetic resonance imaging). The methodology of real-time sono-elastography should be also carefully assessed, with studies that should also aim to test the intra- and interobserver variability of the method.

Gut 2007; 56 (Suppl III) A275

15th United European Gastroenterology Week, October 29th – 31st, 2007, Paris, France

REAL-TIME ELASTOGRAPHY FOR NONINVASIVE ASSESSMENT OF LIVER FIBROSIS IN CHRONIC VIRAL HEPATITIS.

Friedrich-Rust M, Ong MF, Herrmann E, Dries V, Samaras P, Zeuzem S, Sarrazin C.
Department of Internal Medicine II, Saarland University Hospital, Kirrbergerstrasse, Bldg. 41,
Homburg/Saar 66421, Germany. mireen.friedrich.rust@uniklinikum-saarland.de

OBJECTIVE: Recently, transient elastography (FibroScan) has been introduced for noninvasive staging of liver fibrosis. Here, we investigated a novel approach for noninvasive assessment of liver fibrosis using sonography-based real-time elastography, which can be performed with conventional ultrasound probes during a routine sonography examination.

MATERIALS AND METHODS: Real-time elastography was performed in 79 patients with chronic viral hepatitis and known fibrosis stage and in 20 healthy volunteers. A specially developed program was used for quantification of tissue elasticity. Stepwise logistic regression analysis was performed to define an elasticity score using variables with high reproducibility in a preceding analysis of data from 16 different patients. In addition, aspartate transaminase-to-platelet ratio index (APRI) and routine laboratory values were included in the analysis.

RESULTS: The Spearman's correlation coefficient between the elasticity scores obtained using real-time elastography and the histologic fibrosis stage was 0.48, which is highly significant ($p < 0.001$). The diagnostic accuracy expressed as areas under receiver operating characteristic (ROC) curves were 0.75 for the diagnosis of significant fibrosis (fibrosis stage according to METAVIR scoring system [F] $>$ or $=$ F2), 0.73 for severe fibrosis (F $>$ or $=$ F3), and 0.69 for cirrhosis. For a combined elasticity-laboratory score, the areas under the ROC curves were 0.93, 0.95, and 0.91, respectively.

DISCUSSION: Real-time elastography is a new and promising sonography-based noninvasive method for the assessment of liver fibrosis in patients with chronic viral hepatitis.

AJR 2007; 188:758–764

ASSESSMENT OF THE STAGE OF HEPATIC FIBROSIS WITH REALTIME ELASTOGRAPHY

(Translated)

Friedrich-Rust M, Samaras P, Ong MF, Herrmann E, Zeuzem S, Sarrazin C

Clinic for intern medicine II, Universitätsklinikum Saarland.

Background: Realtime Elastography (SonoElastography mode, HITACHI EUB-8500) is a method for calculating the displacement of the ultrasound signals returned from the examined structures before and after compression. Calculation of the reconstructed strain field is encoded in colour from red to blue (red = high-elasticity / soft tissues; blue = low elasticity / hard tissues) and overlaid on the B-mode image allowing the tissue elasticity pertaining to the examined area to be evaluated quantitatively. It is not been shown previously whether Realtime Elastography can be used as a non-invasive assessment of the stage of hepatic fibrosis.

Methods: Seventeen patients suffering from chronic viral hepatitis with a METAVIR score F0 – F4 determined by histology from liver biopsy performed during the previous 14 days; 12 patients with liver cirrhosis confirmed histologically; and as controls, 20 healthy patients, have been examined with Realtime Elastography (HITACHI EUB-8500, probe frequency 13 MHz, offering penetration of 2-5 cm. The average scan area was 350-500 mm², and examination time 5-10 min.). In each case, 10 intercostal elasticity values have been acquired and displayed in colour. For the analysis, only images acquired with standardised compression were retrieved (Compression 3-4 on a scale 1-6). Using a specific computer program, a re-quantification of the encoded colour could be made on a scale from 0 to 1 (0= max. elasticity; 1 = min. elasticity), and various calculations of the elasticity were processed and correlated with the stage of fibrosis on histology.

Results: The results showed optimal correlation allowing the elasticity to be described by the median of all values for each candidate. The mean elasticity values correlated to the stage of fibrosis determined histologically were: for the healthy candidates, $0,66 \pm 0,07$; patients with fibrosis score F0-F1, $0,74 \pm 0,09$; and patients with fibrosis score F2-F4, $0,80 \pm 0,07$ (Kruskal-Wallis-Test $p < 0,001$). The Pearson's correlation coefficient between these parameters and the APRI score (AST to platelet ratio index) was $0,61$ ($p < 0,001$).

Discussion: Realtime-Elastography is a simple, non-invasive method for the assessment of liver fibrosis which can be performed during a normal liver ultrasound examination without the need for any additional equipment. By differentiating between patients with fibrosis score \leq F1 and those with fibrosis score \geq F2 up to F6 (cirrhosis), it could be used as a method to select the therapy for patients suffering from chronic hepatitis avoiding an invasive liver biopsy for many patients.

XVIII th Congress of European Federation of Societies for Ultrasound in Medicine and Biology, 25th – 27th September, 2005, Geneva, Switzerland
